



PATIENT

Coconut Parekh

SPECIES

Canine

BREED

English Bulldog

SEX

M

AGE

2

WEIGHT

56

INTERPRETED BY

R. McKenzie Daniel,
DVM, DABVP
(Canine and Feline)

IMAGING PERFORMED BY

Jenn

HOSPITAL NAME

Rockaway Animal
Hospital

REFERRING VET

Dr Maniar

INVOICE

22924

DATE

11/11/2025

PRESENTING CLINICAL SIGNS

vomiting yellow foam with blood

ULTRASONOGRAPHIC EXAMINATION OF THE ABDOMEN

Urinary System

The urinary bladder, trigone, cystourethral junction, and visible pelvic urethra exhibited normal thickness and tone. Anechoic urine was present in the lumen with no evidence of urine/lumen sediment, mineral, or calculi. The ureteral papillae were normal. The ureters were not visible which is normal. No evidence of inflammatory or neoplastic changes was noted.

Normal size and margination were present in the kidneys. A normal 1:3 cortex / medulla ratio and normal corticomedullary definition were maintained. The echogenicity of the cortex was similar to or slightly less than normal liver parenchyma while the medulla echogenicity was hypoechoic to the cortex with no evidence of pelvic dilation. The left kidney measured 5.5 cm in length. The right kidney measured 5.8 cm in length.

The area of the aortic trifurcation was free of pathology.

The prostate gland was indistinctly visualized, exhibiting subjective expected size and presentation for a young intact male canine without overt pathology.

Adrenal Glands

The left adrenal gland was uniform in size and contour with a uniformly hypoechoic parenchyma. The left adrenal gland measured 0.61 cm width at the caudal pole. The right adrenal gland was uniform in size and contour with a uniformly hypoechoic parenchyma. The right adrenal gland measured 0.76 cm width at the caudal pole.

Spleen

The spleen exhibited a finely textured and homogenous parenchyma which was hyperechoic to the liver and renal cortical parenchyma. The capsule was smooth and regular without apparent expansion. The splenic vasculature at the hilus was normal in volume with no evidence of congestion or thrombosis. Acute to chronic inflammatory, neoplastic, or benign parenchyma changes were not noted.

Liver/Gallbladder

The liver was subjectively normal in size, structure, and contour. The liver parenchyma was uniform and hypoechoic to the spleen with a mild coarse echotexture. Normal vascular volume. The hepatic and portal vasculature were normal in appearance without signs of congestion. The gallbladder was non-distended in size with thin walls and primarily anechoic luminal content. The cystic and common bile ducts were normal.

Gastrointestinal

The stomach was empty in appearance with mild lumen gas. Intact subjective variably prominent stomach wall was present. No evidence of obstruction to pyloric outflow.



PATIENT

Coconut Parekh

The small intestine presented intact wall layering with 1:3 muscularis/mucosa ratio. The lumen of the small intestine was empty with no signs of mechanical/metabolic ileus, obstruction or foreign material.

Normal visible colon wall layers were present with apparent formed feces in lumen.

SPECIES

Canine

Pancreas

The left pancreas was subjective mildly prominent in size with symmetrical contour and mild non-homogenous hypoechoic parenchyma. No evidence of peripancreatic inflammation.

BREED

English Bulldog

Free Abdomen

No omental masses, overt lymphadenopathy or peritoneal effusion was present.

SEX

M

Primary

- Empty gastrointestinal tract with mild gastritis pattern
- Mild prominent hypoechoic left pancreas-patient variant, possible low grade inflammation

AGE

2

INTERPRETATION OF THE FINDINGS & FURTHER RECOMMENDATIONS

Gastrointestinal support and empirical therapy for gastritis should prove beneficial. No evidence of gastrointestinal foreign material or obstructive pattern. A spec CPL could be considered to correlate with pancreatic presentation.

WEIGHT

56

INTERPRETED BY

R. McKenzie Daniel,
DVM, DABVP
(Canine and Feline)

IMAGING PERFORMED BY

Jenn

HOSPITAL NAME

Rockaway Animal
Hospital

REFERRING VET

Dr Maniar

INVOICE

22924

DATE

11/11/2025



PATIENT

Coconut Parekh

SPECIES

Canine

BREED

English Bulldog

SEX

M

AGE

2

WEIGHT

56

INTERPRETED BY

R. McKenzie Daniel,
DVM, DABVP
(Canine and Feline)

IMAGING PERFORMED BY

Jenn

HOSPITAL NAME

Rockaway Animal
Hospital

REFERRING VET

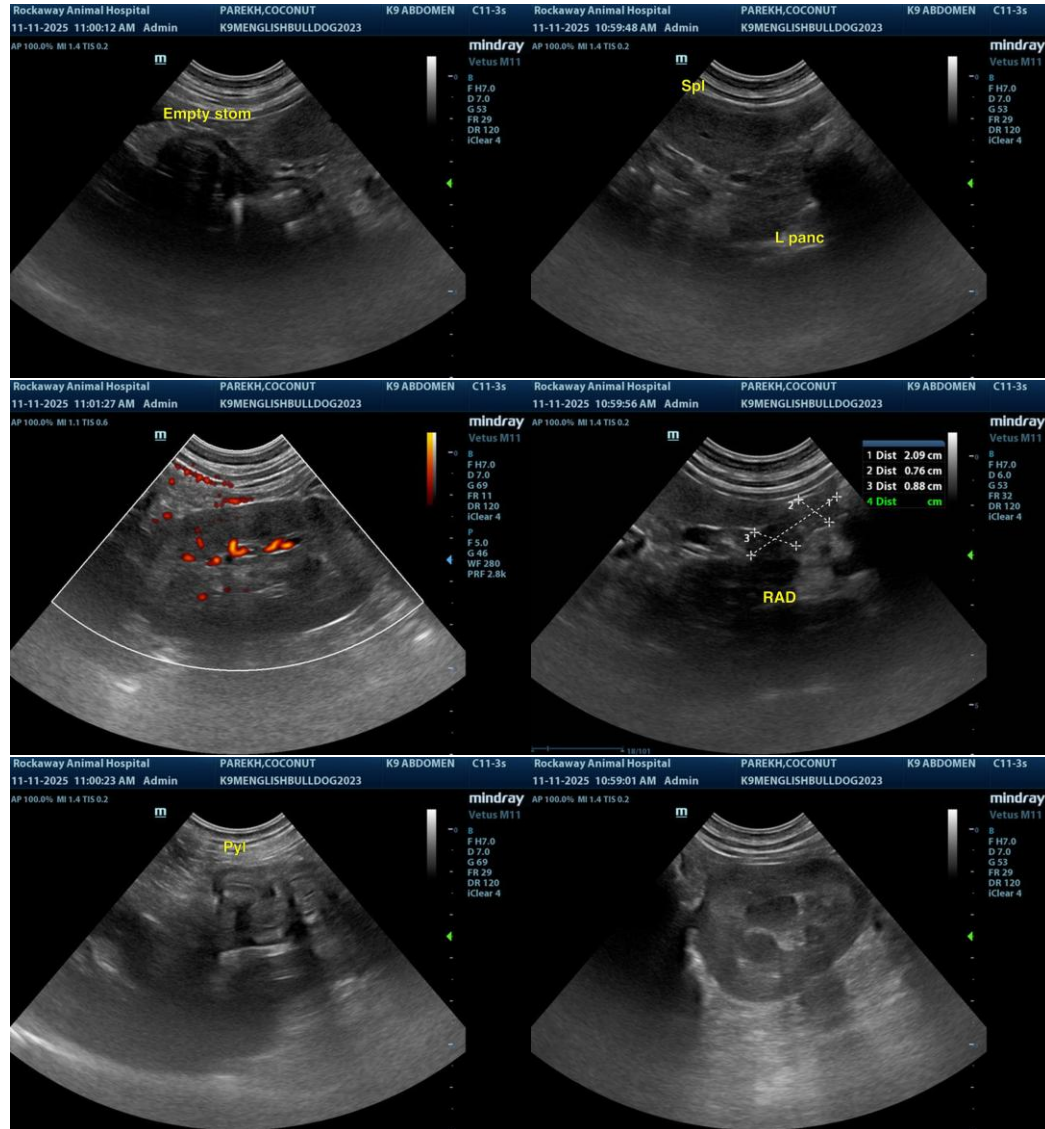
Dr Maniar

INVOICE

22924

DATE

11/11/2025





PATIENT

Coconut Parekh

SPECIES

Canine

BREED

English Bulldog

SEX

M

AGE

2

WEIGHT

56

INTERPRETED BY

R. McKenzie Daniel,
DVM, DABVP
(Canine and Feline)

IMAGING PERFORMED BY

Jenn

HOSPITAL NAME

Rockaway Animal
Hospital

REFERRING VET

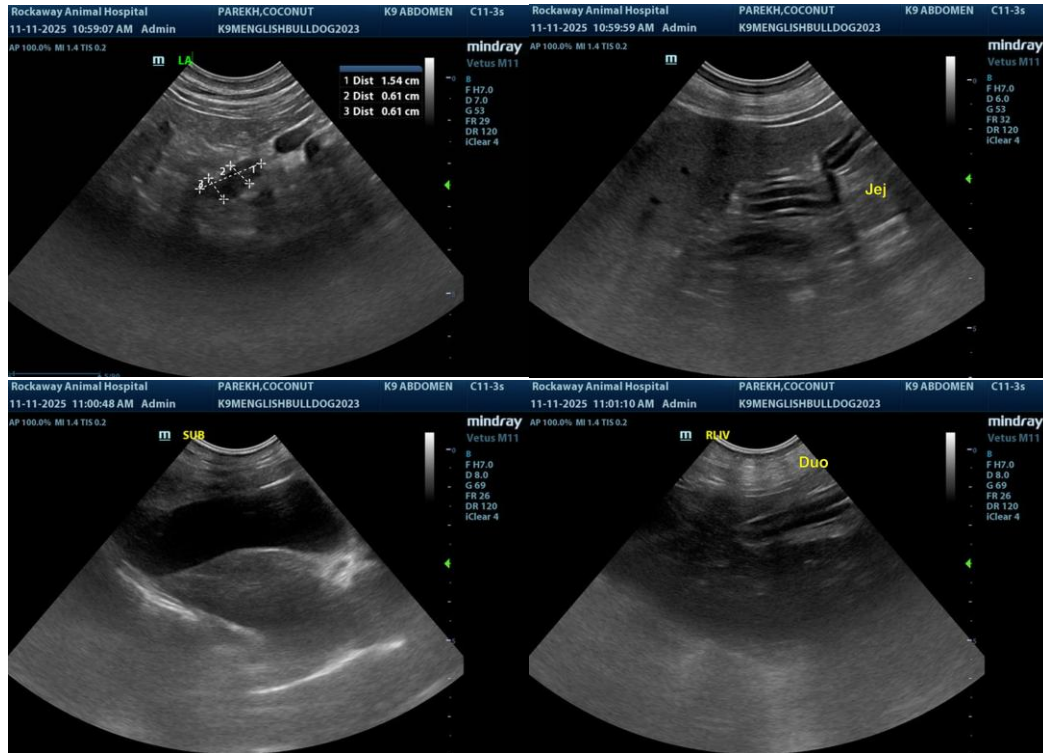
Dr Maniar

INVOICE

22924

DATE

11/11/2025



The information and recommendations provided are based on the images presented by the referring veterinarian/sonographer. No evaluation can be communicated regarding pathology that was not visible in the image/video clips provided.

Thank you for this referral. If the clinical or image interpretation does not parallel your findings or if I can be of any further assistance, please contact me.

R. McKenzie Daniel, DVM, DABVP (Canine/Feline Practice)
info@sonopath.com